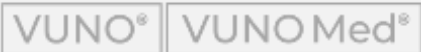



VUNO Med[®] - Fundus AI[™] For HUVITZ Fundus Camera Product Introduction



Registered in R.O.K. & U.S. Patent and Trademark Office

Copyright Notice

The contents of these documents, including (but not limited to) all written material, images, and photos are copyright of VUNO, Inc. Unauthorized copying, reproduction, modification, republishing, transmission or distribution of any material without the prior written content of VUNO, Inc. constitute an infringement of intellectual property rights and may result in a criminal or civil action in accordance with Article 98 of Copyright Act. Copyright (C) VUNO Inc. All rights reserved.

Contents

- 1 **Current Practice**
- 2 **Product Features**
- 3 **Value Proposition**
- 4 **Precautions**

VUNO®



1 Current Practice

· Fundus Examination

- A diagnostic procedure that assesses the retina, optic disc, macula, choroid, etc. with a camera¹
- To diagnose various eye diseases or check the progress of the disease by examining them¹

🔧 Procedure

1. It takes approximately **5 ~ 10 minutes**¹
2. Place a patient's chin in the chin rest and forehead against the bar
3. Focus, align the camera and then press the shutter release¹
4. Examine both eyes¹

📝 Remarks

1. A patient needs to fix gaze in order to be properly examined¹
2. Mydriatic or non-mydriatic method is chosen depending on clinical setting and patient pupil size¹
3. A primary eye exam to diagnose 3 most common diseases that can lead to blindness: diabetic retinopathy, age-related macular degeneration and glaucoma.²



Figure 1. Huvitz Fundus Camera HFC-1 with VUNO Med® - Fundus AI™

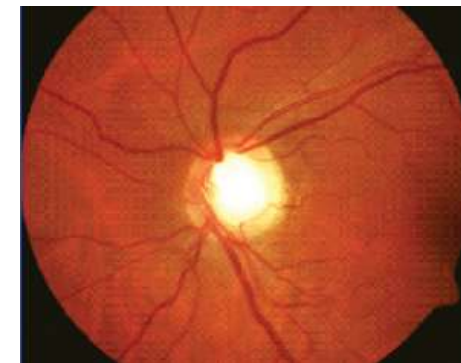


Figure 2. Glaucoma suspicious optic disc³

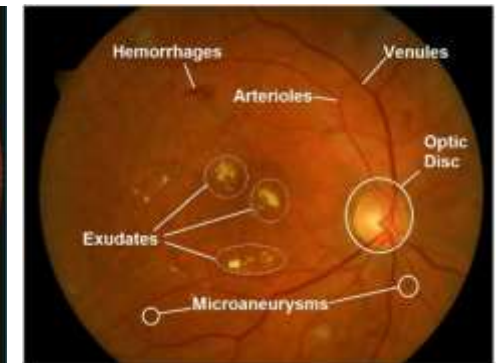


Figure 3. Diabetic Retinopathy⁴

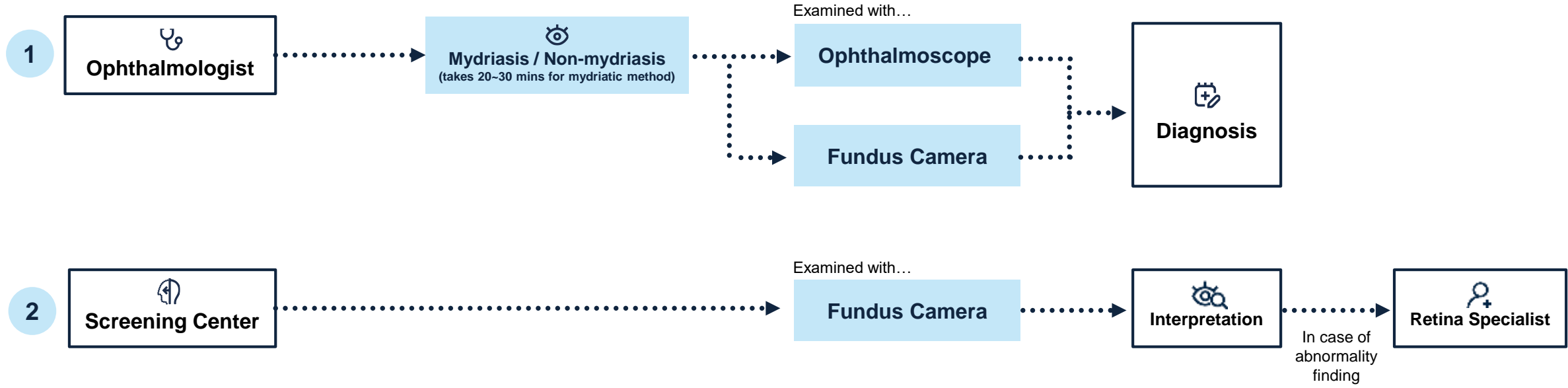
1) <http://www.amc.seoul.kr/asan/healthinfo/management/managementDetail.do?managementId=414>

2) KyoungJi Woo, et al. National Health and Nutrition Survey on the Current Status and Management Level of Eye Disease. Health and Disease Weekly (12)22

3) <https://www.reviewofophthalmology.com/article/how-to-evaluate-the-suspicious-optic-disc>

4) Dai L, et al. Clinical Report Guided Retinal Microaneurysm Detection With Multi-Sieving Deep Learning. IEEE Trans Med Imaging. 2018 May;37(5):1149-1161

1 Current Practice



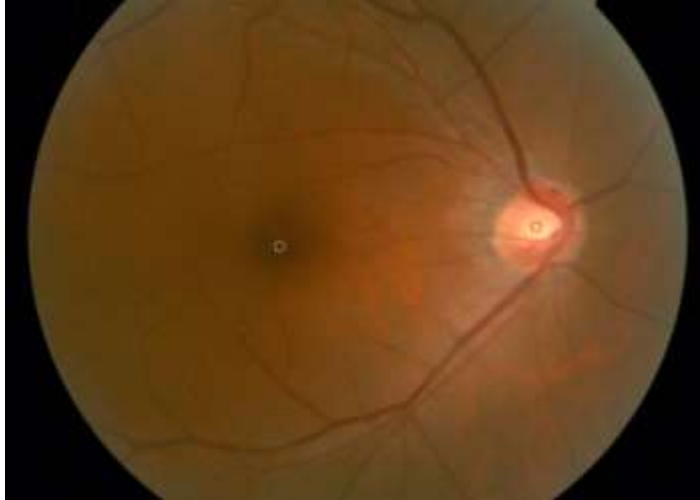
Practice	Pain Points
<ul style="list-style-type: none"> An ophthalmologist can directly examine the eyes by using special instruments such as schematic glasses, and dipole, and take a photograph of the fundus with a special camera for fundus examination In health screening centers, only preliminary screening is available, and patients are informed of the need for further examination through retina specialists (or ophthalmologists) for accurate diagnosis. 	<ul style="list-style-type: none"> It takes extra time for examination with mydriasis For health screening centers, accurate diagnosis may be difficult because it depends on retina specialists' (or ophthalmologists) experience In case of ophthalmologist with less experience, possible to miss some abnormal findings

1) Wonki Lee. Office Workers' Health Examination Results, Ophthalmological examination mandatory for suspected blindness related eye disease. Diabetes and Health Nov 2019. p8-9
 2) <http://www.amc.seoul.kr/asan/healthinfo/management/managementDetail.do?managementId=414>

1 Current Practice

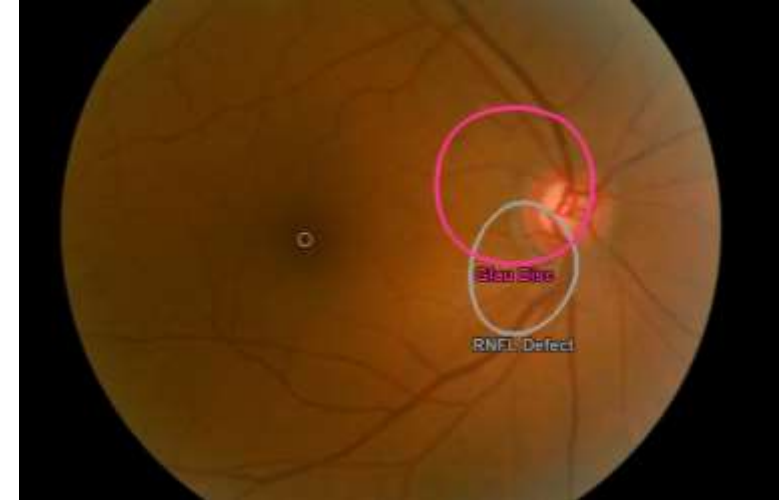
Without VUNO Med® - Fundus AI™

- Only preliminary screening is available, and patients are informed of the need for further examination through retina specialists (or ophthalmologists) for accurate diagnosis.
- In case of ophthalmologist with less experience, possible to miss some abnormal findings



With VUNO Med® - Fundus AI™

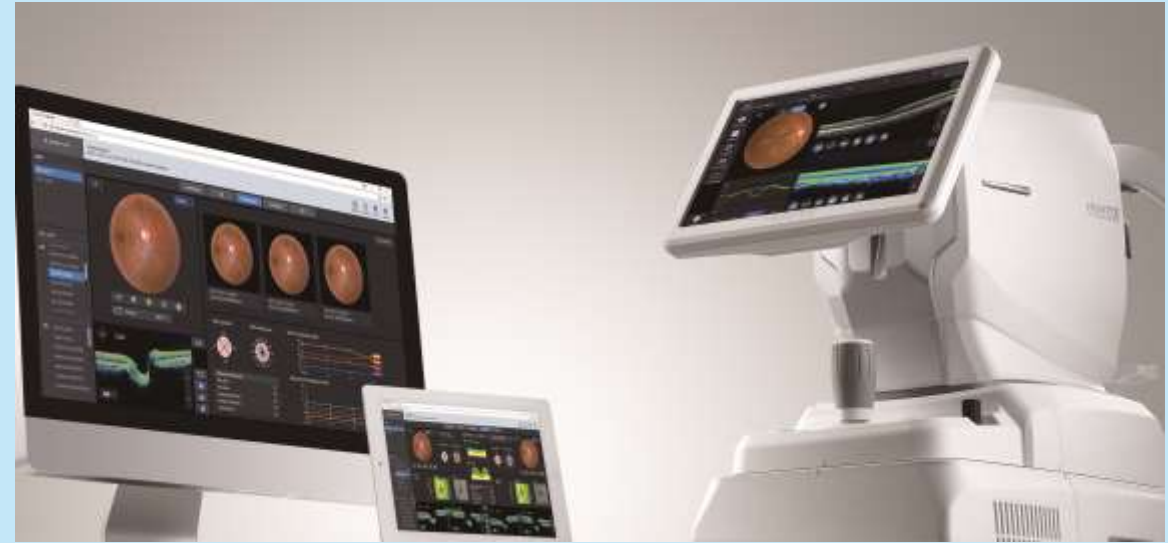- It is possible to be assisted diagnosis of 12 abnormalities from the solution
- It helps reduce the burden to read fundus images



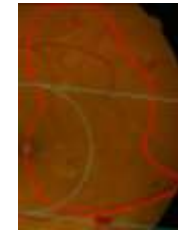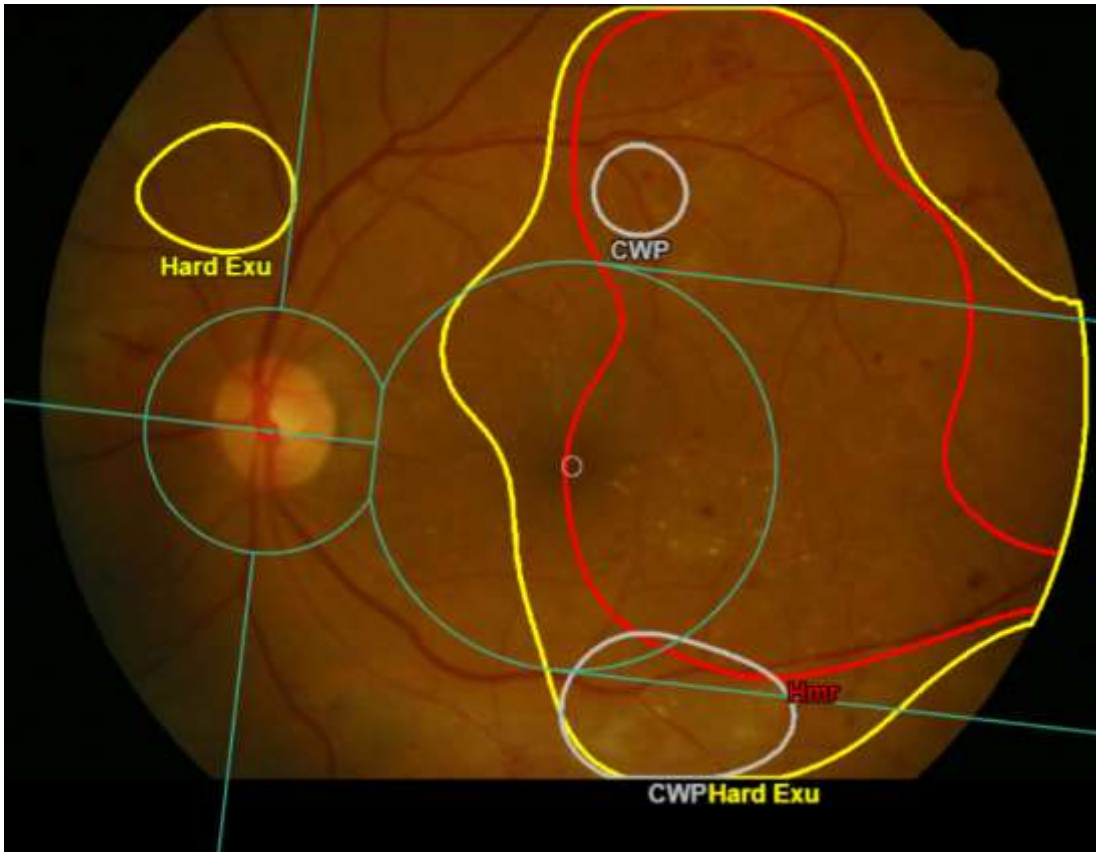2 Product Features

2-1 Clinical Support

2-2 Reliability



- **Detect Abnormality** • Detects 12 types of fundus abnormalities in different colors



Hemorrhage



Cotton Wool Patch

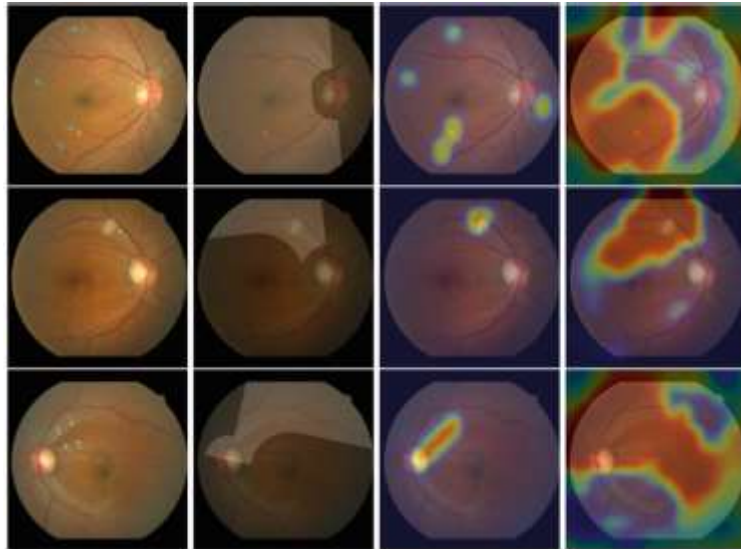


Hard Exudate

- Hemorrhage
- Hard Exudate
- Cotton Wool Patch
- Drusen
- Membrane
- Macular Hole
- Myelinated Nerve Fiber
- Chorioretinal Atrophy
- Vascular Abnormality
- Retinal Nerve Fiber Layer Defect
- Glaucomatous Disc Change
- Non-glaucomatous Disc Change

· Training Dataset

- **103,262 Fundus images¹**
- **28 Ophthalmologists participated in the research¹**
: 16 Retina specialists, 9 Glaucoma specialists, 3 Corneal specialists¹
- Collected from the medical check-up center and ophthalmology outpatient clinic of Seoul National University Bundang Hospital¹



Seoul National University Bundang Hospital Datasets			
	Training and Validation Set	Majority Rule Test Set (≥ 2 Agreements)	Unanimity Rule Test Set (3 Agreements)
Total no. of fundus images	103 262		
Total no. of gradable images (%)	95 350 (92.3)		
Total no. of right eyes	47 586		
Total no. of left eyes	47 764		
No. of patients	47 022		
Age, mean \pm SD	51.5 \pm 25.4		
No. of women (%)	22 808 (48.5)		
Location of hospital	Korea		
Hemorrhage	3846/78 315 (4.9)	429/8642 (5.0)	286/8499 (3.4)
Microaneurysms	—	—	—
Hard exudate	1930/79 071 (2.4)	234/8780 (2.7)	158/8704 (1.8)
Cotton-wool patch	648/79 626 (0.8)	63/8858 (0.7)	30/8825 (0.3)
Drusen	7591/72 514 (10.5)	800/8125 (9.8)	376/7701 (4.9)
Membrane	3110/78 202 (4.0)	338/8739 (3.9)	191/8592 (2.2)
Macular hole	291/79 990 (0.4)	38/8859 (0.4)	16/8837 (0.2)
Myelinated nerve fiber	259/80 275 (0.3)	16/8939 (0.2)	8/8931 (0.1)
Chorioretinal atrophy	2642/77 749 (3.4)	295/8639 (3.4)	144/8488 (1.7)
Vascular abnormality	596/79 226 (0.8)	76/8829 (0.9)	32/8785 (0.4)
RNFL defect	1687/77 406 (2.2)	199/8603 (2.3)	66/8470 (0.8)
Glaucomatous disc change	3040/75 344 (4.0)	318/8363 (3.8)	111/8156 (1.4)
Nonglaucomatous disc change	962/77 509 (1.2)	104/8650 (1.2)	23/8569 (0.3)

1) Son J, et al. Development and Validation of Deep Learning Models for Screening Multiple Abnormal Findings in Retinal Fundus Images. Ophthalmology (2019).

2 Product Features | Reliability



- **Proven Performance with Validation**
 - **Stable performance from In-House Test Set^{*1}** (AUROC 96.2 – 99.9%)
 - **Stable performance from External Datasets^{#1}** (AUROC 94.7 – 98.0%)

Table 1. AUROC for each finding in the SNUBH dataset and external datasets¹

	SNUBH Reference Dataset		External Datasets	
	Majority Rule (≥2 agreements)	Unanimity Rule (3 agreements)	IDRiD	e-optha
Hemorrhage	99.3 (96.7-99.9)	99.7 (97.3-100.0)	98.0 (81.0-99.9)	94.7(84.9-98.9)
Hard Exudate	99.8 (97.4-100.0)	98.0 (96.4-100.0)	98.0 (76.8-100.0)	96.5(73.5-100.0)
Cotton Wool Patch	99.3 (94.9-100.0)	99.7 (94.7-100.0)	95.7 (69.8-99.8)	
Drusen	98.2 (96.4-99.2)	99.0 (96.3-99.9)	-	-
Membrane	98.9 (96.1-99.7)	99.7 (96.9-100.0)	-	-
Macular Hole	99.9 (92.9-100.0)	99.9 (88.8-100.0)	-	-
Myelinated Nerve Fiber	98.7 (89.7-100.0)	99.9 (92.3-100.0)	-	-
Chorioretinal Atrophy	99.6 (97.1-100.0)	99.9 (96.5-100.0)	-	-
Vascular Abnormality	96.2 (91.4-99.1)	97.9 (90.1-100.0)	-	-
RNFL defect	98.3 (95.3-99.5)	99.5 (94.9-100.0)	-	-
Glaucomatous Disc Change	98.2 (95.8-99.3)	99.5 (96.1-100.0)	-	-
Non-glaucomatous Disc Change	97.7 (94.8-99.4)	99.2 (93.6-100.0)	-	-

^{*}Seoul National University Bundang Hospital dataset #IDRiD, e-optha datasets

¹⁾ Son J, et al. Development and Validation of Deep Learning Models for Screening Multiple Abnormal Findings in Retinal Fundus Images.Ophthalmology (2019).

· Minimized Compatibility Issues

- Fundus images taken with more than **5 digital fundus cameras were used**¹
- **Mydriasis does not make a significant difference in performance**² (Table 1.)
- **Optimized performance is expected when the same types of cameras used for training are used.**

Table 1. Characteristics of included studies in systematic review²

First Author, Reference	Factor Addressed of Training/ Testing Dataset	Data Points	Training Dataset	Number of Images (Testing Dataset)	Testing Dataset	Number of Images (Testing Dataset)	Outcome Measures	Results	Implications
Bawankar	Mydriasis (Testing)	Non-mydriasis (vs ETDRS Mydriatic Reference Standard)	Eye-PACS1, India	80,000	India	1084	SN, SP	SN 91.2%, SP 96.9%	Despite no mydriasis of testing able to Perform highly when compared to mydriatic 7-field ETDRS grading reference standard Mydriasis may not be required for optimal performance.
		Mydriatic	EyePACS	128,175	Eye-PACS1	4236	SN, SP	SN 89.6%, SP 97.9%	
Gulshan	Mydriasis (Testing)	Non-Mydriatic				4534		SN 90.9%, SP 98.5%	
		Both				8770		SN 90.1%, SP 98.2%	

1) Son J, et al. Development and Validation of Deep Learning Models for Screening Multiple Abnormal Findings in Retinal Fundus Images. Ophthalmology (2019).

2) Yip M, et al. Technical and imaging factors influencing performance of deep learning systems for diabetic retinopathy. npj Digital Medicine (2020) 3:40.

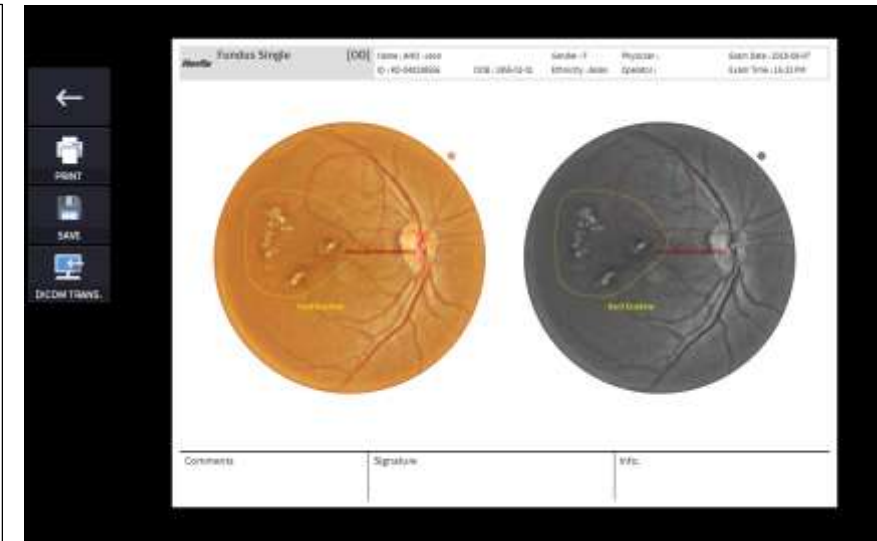
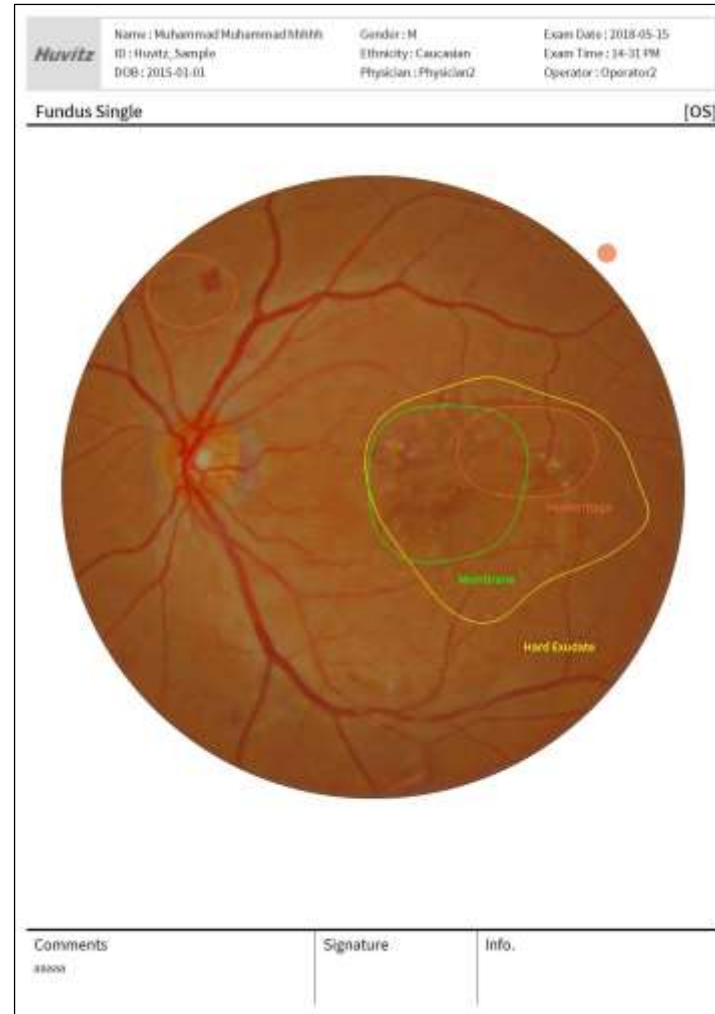
· Publications

#	Year	Jour./Conf.	Status	Type	Title
1	2018	JKMS	Published	Journal	A Novel Fundus Image Reading Tool for Efficient Generation of a Multi-dimensional categorical Image Database for Machine Learning Algorithm Training
2	2018	MICCAI	Published	Workshop	Classification of Findings with Localized Lesions in Fundoscopic Images using a Regionally Guided CNN
3	2018	MICCAI	Published	Workshop	An Efficient and Comprehensive Labeling Tool for Large-Scale Annotation of Fundus Images
4	2018	JDI	Published	Journal	Towards Accurate Segmentation of Retinal Vessels and the Optic Disc in Fundoscopic Images with Generative Adversarial Networks
5	2018	JDI	Published	Journal	Laterality Classification of Fundus Images Using Interpretable Deep Neural Network
6	2019	MIA	Published	Journal	REFUGE Challenge: A unified framework for evaluating automated methods for glaucoma assessment from fundus photographs
7	2019	MIA	Published	Journal	IDRiD: Diabetic Retinopathy – Segmentation and Grading Challenge
8	2019	Ophthalmology	Published	Journal	Development and Validation of Deep Learning Models for Screening Multiple Abnormal Findings in Retinal Fundus Images

2 Product Features | Efficiency

Result Report

- Displayed 12 abnormalities in fundus image
- Customized in doctor's comments



3 Value Proposition

Autonomous & Clinically Aligned

- Automatic fundus region marking and abnormality detection can assist doctors in the diagnosis of eye diseases.
- Since VUNO Med® - Fundus AI™ has been trained on 103,262 fundus images labelled by 57 ophthalmologists, risk management can be expected in clinical areas.

Cost / Time - Efficient

- Analyzes all patients in the patient list with a single click
- Allows doctors to check the presence of an abnormality at a glance according to the clinical environment
- Finds abnormalities within 2 seconds per image with 95% accuracy.¹

Agnostic to Huvitz Fundus Camera HFC-1

- Optimal performance is expected when using a Huvitz Fundus Camera HFC-1 that was used in training.

1) May vary depending on internet and/or server environment

Performance-related

- 1) No performance guarantees on images of patients under the age of 19
- 2) Analysis results may vary depending on the data format (DICOM, PNG, JPG) and the resolution of the imported images (DICOM format is recommended as PNG, JPG formats tend to have resolution)
- 3) All input files have to be standard images taken in a proper manner; otherwise, they can lead to “Ungradable” results

*** Ungradable Cases:**

- ① Darkened image due to insufficient dilation of pupils (small pupil)
- ② Blurred retina due to media opacity
- ③ Non-macula-centered image of the macula core
- ④ Images where some of the main reading areas are not taken or are difficult to identify (stains on lenses, excessive light smudging)

General

- 1) VUNO Med[®] - Fundus AI[™] is not a stand-alone diagnostic tool that can make a decision alone; hence requires professional judgement from the user.
- 2) There is a chance of misdiagnosis when a medical decision of diagnosis and treatment is made solely based on this solution.
- 3) The user is held responsible for the VUNO Med[®] - Fundus AI[™] assisted final diagnosis.



Thank you!

T 02.515.6646

E hello@vuno.co

H www.vuno.co



Registered in R.O.K. & U.S. Patent and Trademark Office

Copyright Notice

The contents of these documents, including (but not limited to) all written material, images, and photos are copyright of VUNO, Inc. Unauthorized copying, reproduction, modification, republishing, transmission or distribution of any material without the prior written content of VUNO, Inc. constitute an infringement of intellectual property rights and may result in a criminal or civil action in accordance with Article 98 of Copyright Act. Copyright (C) VUNO Inc. All rights reserved.